

Fetal enterolithiasis: prenatal sonographic and MRI diagnosis in two cases of urorectal septum malformation (URSM) sequence

Lubusky M.^{1,2}, Prochazka M.³, Bunc M.⁴

Dept. of Obstetrics and Gynaecology, University Hospital, Olomouc, Czech Republic

Dept. of Medical Genetics and Fetal Medicine, University Hospital, Olomouc, Czech Republic

Dept. of Radiology, University Hospital, Olomouc, Czech Republic

*Dept. of Pathology, University Hospital, Olomouc, Czech Republic*⁴

Enterolithiasis (multiple calcifications of intraluminal meconium) is a rare, prenatal ultrasonographic finding and mostly appears to result from the mixing of stagnant urine and meconium *in utero*. The presence of the intraluminal calcifications in a dilated loop of intestine, particularly with an associated urinary tract abnormality, should suggest a fistula between the urinary and gastrointestinal tracts.

In our reports we present two cases of enterolithiasis in the fetuses, one with partial and the other complete urorectal septum malformation (URSM) sequence, which were detected prenatally by ultrasound scan and magnetic resonance imaging (MRI).

Figure 1. Case 1. Coronal ultrasound pelvic scan of the twin A showing lower abdominal cystic mass with echogenic foci representing enterolithiasis

Figure 2. Case 1. Magnetic resonance imaging (MRI) demonstrates dilated distal bowel loops with enterolithiasis in twin A

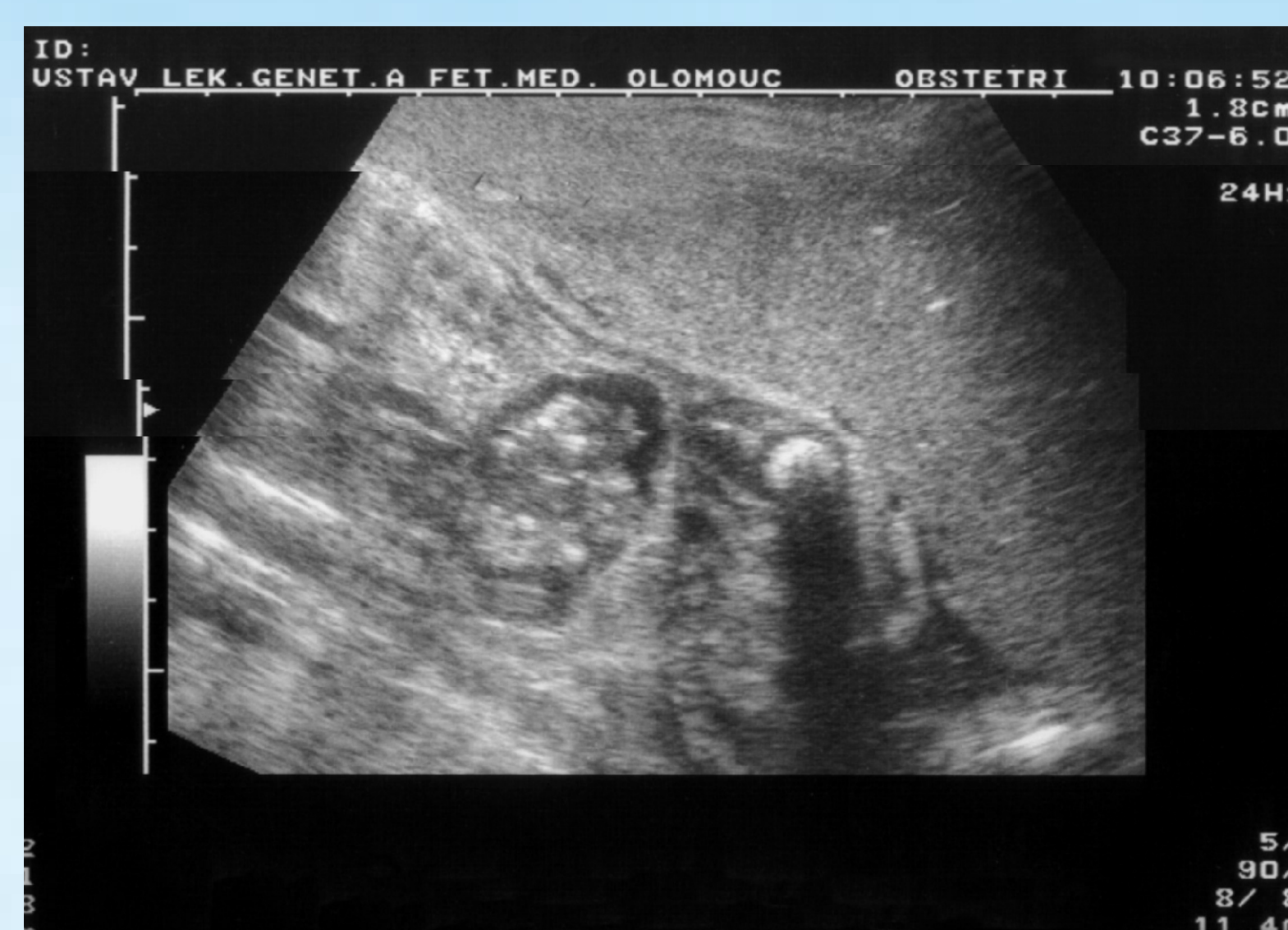

Figure 1

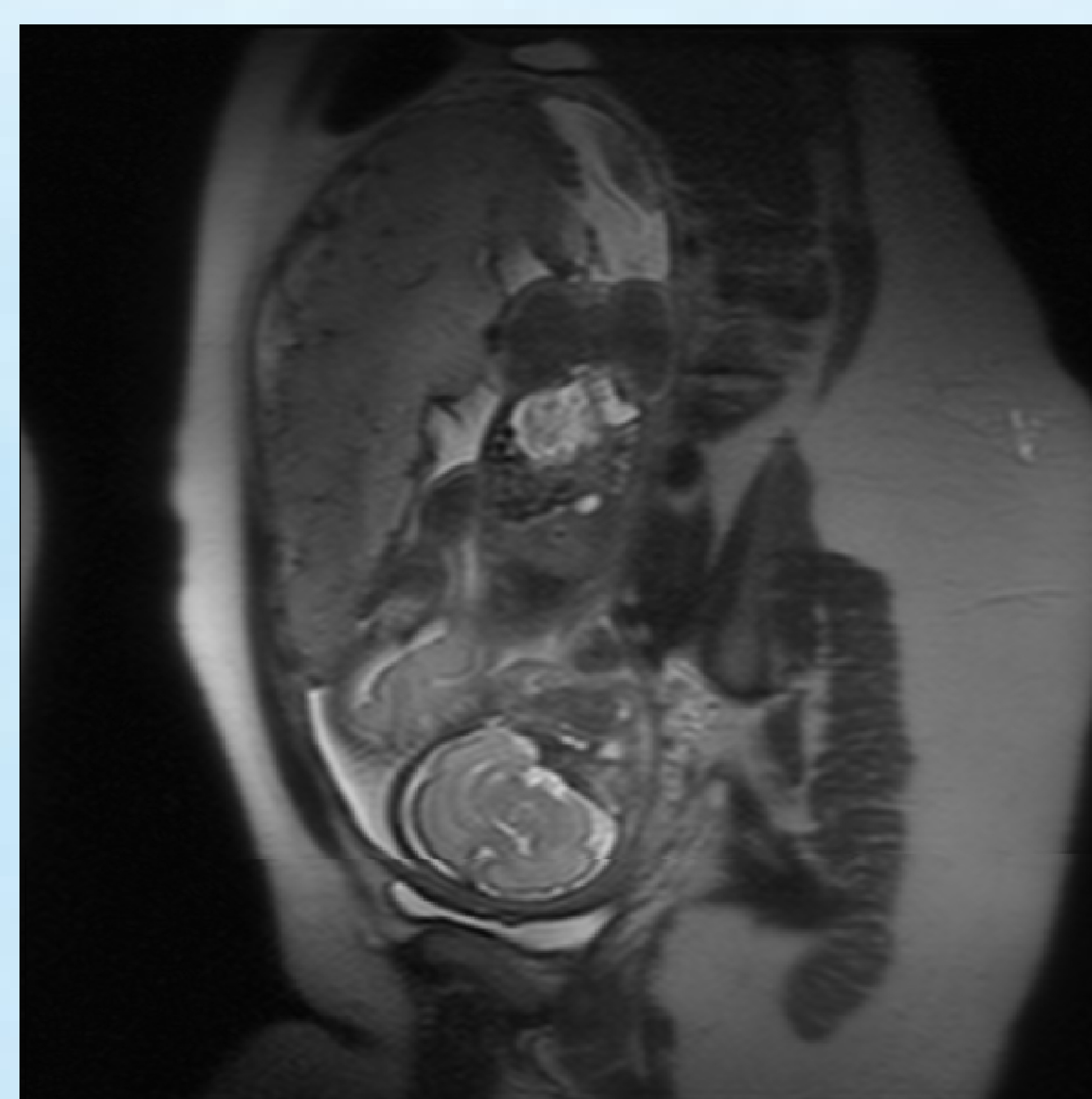


Figure 2

Case 1

The mother, a 19-year-old Caucasian woman, gravida 1, para 0, referred to the ultrasound unit of the department of medical genetic and fetal medicine at 18 weeks of spontaneous pregnancy for routine screening. There was no family history of congenital malformations. On sonographic examination, a monozygotic, diamniotic twin pregnancy was diagnosed. Twin A had dilated distal bowel loops with enterolithiasis (an ultrasonographic examination revealed an echogenic bowel with multiple foci of calcified meconium intraluminally) (Figure 1). Twin B had dilated distal bowel loops. A possible diagnosis of anal atresia was made. The genitalia could not be clearly determined. In view of the abnormal sonographic findings, amniocentesis was performed. Both fetuses had a normal 46,XY karyotype. The patient was referred to the high-risk clinic. Fetal biometry was appropriate for gestational age and a normal amount of amniotic fluid was observed. To further rule out anorectal malformation MRI was performed and demonstrated dilated distal bowel loops (with enterolithiasis in twin A) (Figure 2). The parenchyma of the kidneys and urinary bladder appeared normal. Pregnancy was terminated by caesarean section at 35 weeks of gestation after premature rupture of membranes. Twin A was a male, weighing 1950 g. Twin B weighed 2350 g. Post-partum examination revealed close placental insertions of both umbilical cords, each containing three vessels. Over a length of 25 cm the umbilical cords, separated by amniotic membranes, ran in such close proximity that they appeared to have a common course. The monozygotic, diamniotic twin pregnancy was certified and concordant fetal abnormalities were diagnosed. Both neonates had a single perineal opening that drained a common cloaca in combination with anal atresia. The cloaca drained the bladder and colon separately. There was a short and hypoplastic colon, dilated distal bowel loops (in the twin A with enterolithiasis), and a fistula between the colon and the bladder. External genital malformations included: cloaca with a single opening, perineal hypospadias, bifid scrotum, and penoscrotal transposition. There were also pelvic and sacral abnormalities. The diagnosis of partial URSM sequence was confirmed postnatally and the babies underwent corrective urogenital and intestinal surgeries. At present they are 2 years of age and their health condition is generally good.

The prenatal diagnosis (detection) of enterolithiasis carries a poor prognosis. It is a warning sign for large bowel obstruction with or without enterourinary fistula. Therefore, adequate gastrointestinal and urologic studies must be undertaken after birth for final diagnosis. There is a high mortality rate in the reported cases, mostly attributed to associated anomalies, and all survivors required neonatal surgery.

Figure 3. Case 2. Transverse sonographic view of the fetal abdomen showing dilated loops of bowel with multiple echogenic foci of intraluminal calcified meconium (enterolithiasis)

Figure 4. Case 2. Magnetic resonance imaging (MRI) demonstrates dilated bowel loops with enterolithiasis

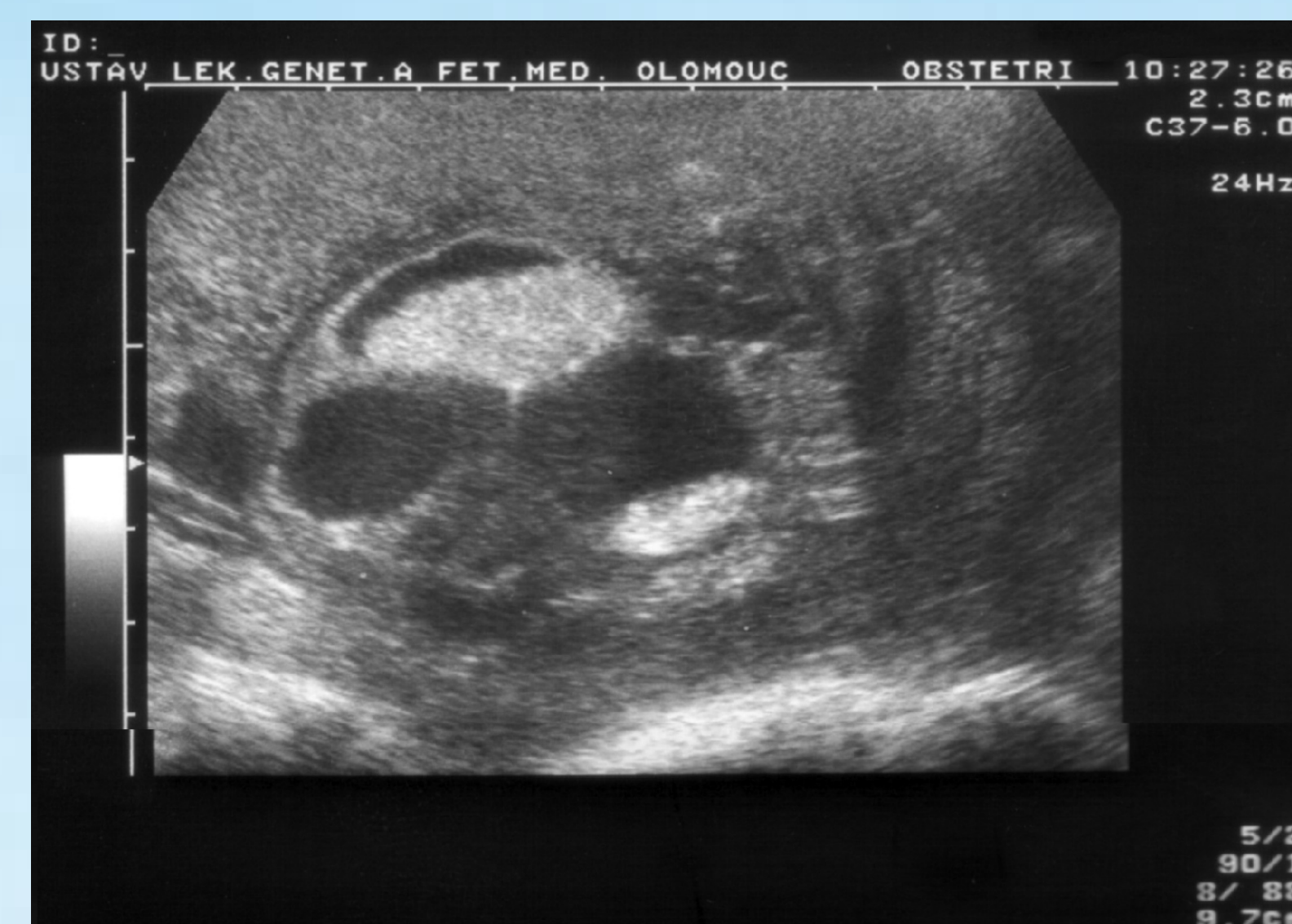

Figure 3

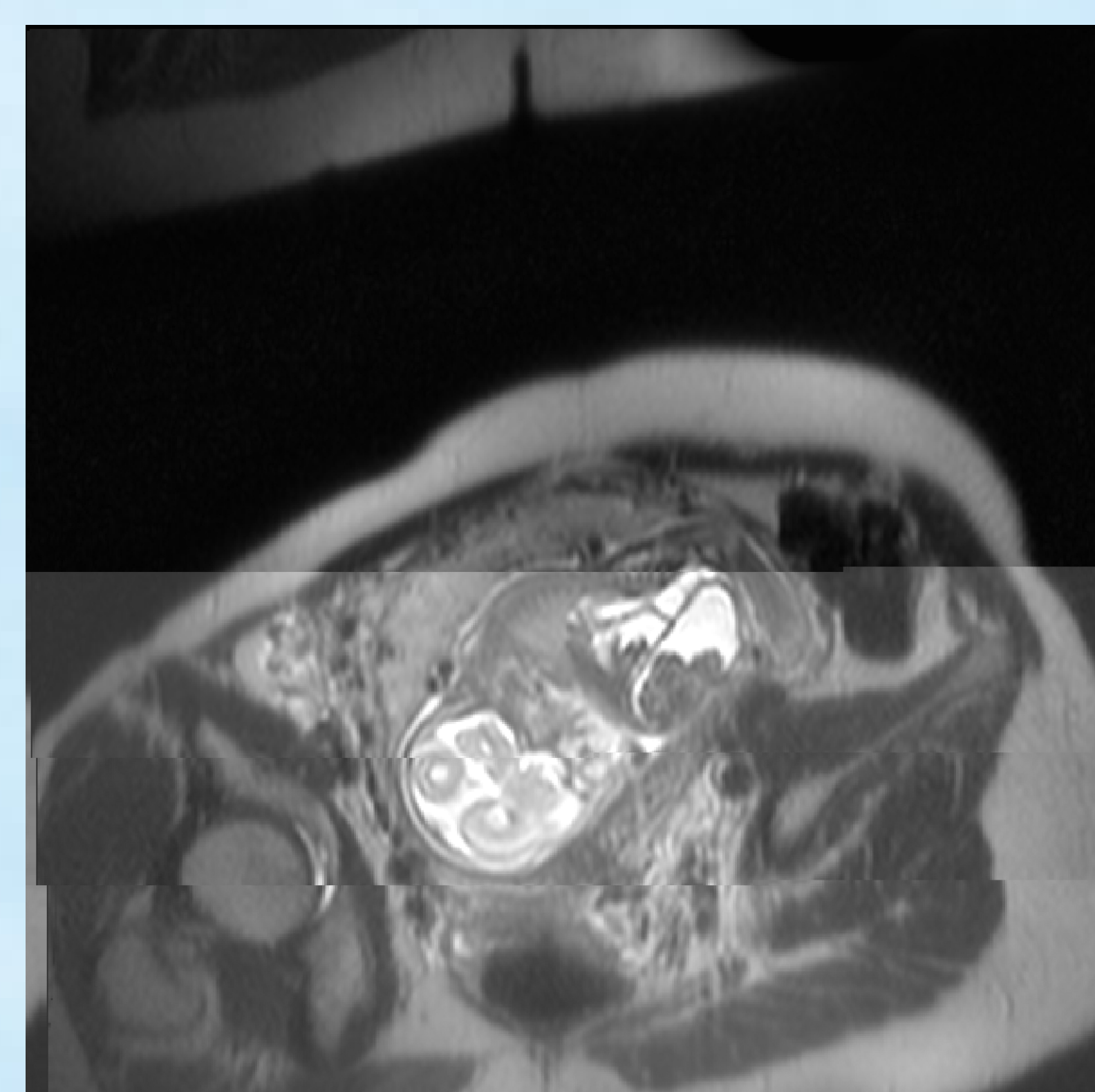


Figure 4

Case 2

The mother, a 28-year-old Caucasian woman, gravida 2, para 1, presented to the ultrasound unit of the department of medical genetic and fetal medicine at 20 weeks of a spontaneous pregnancy because of oligohydramnios. On sonographic examination, fetal biometry was appropriate for gestational age and a severe oligohydramnios to anhydramnios was observed. The fetus had dilated bowel loops with enterolithiasis (an ultrasonographic examination revealed multiple echogenic foci of calcified meconium intraluminally) (Figure 3). There was right hydronephrosis (renal pelvis dilatation in anteroposterior diameter up to 10 mm, with no parenchyma reduction or calices distention), as well as a dilated ureter up to 8 mm. The parenchyma of the left kidney appeared normal without ureter distention. The urinary bladder was not visible and the genitalia could not be clearly determined. A possible diagnosis of complete URSM sequence was made. MRI was performed and demonstrated dilated bowel loops with enterolithiasis; however, the urinary bladder remained undetectable (Figure 4). Due to parents' demand the pregnancy was terminated. The diagnosis of complete URSM sequence was confirmed postnatally. External examination showed ambiguous (unrecognizable) genitalia, no phallic structure, and no perineal or anal opening (blank perineum). On autopsy pulmonary hypoplasia was not described. Autopsy showed abdominal testes, distention of the urinary bladder (35 x 15 mm) with outlet obstruction, a fistula between the dilated distal small intestine (terminal ileum) and the bladder, distal colon and rectal atresia. The colon ending in a dilated meconium-filled, blind pouch. Intraluminal calcification of meconium was described in the dilated colon and the bladder. There was right hydronephrosis (dilatation of the renal pelvis without parenchyma reduction and distention of calices) and a dilated ureter without distinct connection to the bladder. The parenchyma of the left kidney was normal and the ureter typically drained to the bladder. Dysplastic changes in both kidneys were not described. The diagnosis of a megacystis with enterolithiasis was set postnatally according to post-mortem examination. Chromosome analyses were not done.